

Cranial Cruciate Ligament Disease

Basics

OVERVIEW

- The “stifle” is the knee joint of the dog; it is the joint between the large upper thigh bone (the femur) and the two lower leg bones (tibia and fibula)
- A “ligament” is a band of connective or fibrous tissue that connects two bones or cartilage at a joint; the “cranial cruciate ligament” is the ligament that connects the inner, back part of the femur with the tibia—it helps to stabilize the stifle joint
- “Cranial cruciate ligament disease” is the sudden (acute) or progressive failure of the cranial cruciate ligament, which results in partial to complete instability of the stifle (knee) joint
- “Cranial cruciate rupture” is the tearing of the cranial cruciate ligament; it is the most common cause of rear-leg lameness in dogs and a major cause of degenerative joint disease (progressive and permanent deterioration of joint cartilage) in the stifle joint; rupture may be partial or complete



GENETICS

- Unknown
- May be important in increasing the likelihood of active stifle restraint deficiencies and/or conformation abnormalities

SIGNALMENT/DESCRIPTION OF PET

Species

- Dogs
- Cats—uncommon

Breed Predilections

- All susceptible
- Rottweilers and Labrador retrievers—increased incidence when less than 4 years of age

Mean Age and Range

- Dogs, greater than 5 years of age
- Large-breed dogs—1–2 years of age

Predominant Sex

- Spayed female

SIGNS/OBSERVED CHANGES IN THE PET

- Related to the degree of rupture (partial versus complete), the mode of rupture (sudden [acute] versus long-term [chronic]), the presence of other injury to the stifle, and the severity of inflammation and degenerative joint disease (progressive and permanent deterioration of joint cartilage)
- History of athletic or traumatic events—generally precede sudden (acute) injuries
- Normal activity resulting in sudden (acute) lameness—suggests degenerative rupture; “degeneration” is the decline or loss of function or structure of a tissue
- Subtle to marked intermittent lameness (for weeks to months)—consistent with partial tears that are progressing to complete rupture
- Sudden (acute) cranial cruciate rupture results in non-weight-bearing lameness, fluid buildup in the joint (known as “joint effusion”) and the affected leg held in partial flexion while standing
- “Cranial drawer test”—specific manipulation evaluating the status of the cranial cruciate ligament; diagnostic for cranial cruciate rupture
- Decrease in muscle mass (known as “muscle atrophy”) in the rear leg—especially the quadriceps muscle group

CAUSES

- Trauma (repeat jumping, twisting etc.)
- Repetitive microinjury to the cranial cruciate ligament (the dog that has jumped on/off couch for 9 years!)
- Conformation abnormalities (how the bones etc. line up)

RISK FACTORS

- Obesity
- Kneecap (known as the “patella”) dislocation (known as a “patellar luxation”)
- Poor conformation
- Abnormalities of the bones making up the stifle

Treatment

ACTIVITY

- Restricted—with conservative medical treatment and immediately after surgical stabilization; duration of activity restriction depends on method of treatment and progress of pet

DIET

- Weight control—important for decreasing stress on the stifle joint

SURGERY

- Stabilization surgery—recommended for all dogs; speeds rate of recovery; reduces degenerative joint changes; enhances function
- Various surgical techniques are available to treat cranial cruciate rupture

Extra-Articular Methods (lateral stabilization)

- Variety of techniques that use a heavy-gauge implant to tether the tibia to the femur and restore stability
- Implant material—placed in the approximate plane of the cranial cruciate ligament attachments to the bones (femur and tibia)

Intra-Articular Methods

- Designed to replace the cranial cruciate ligament anatomically
- Uses various materials to “act” as the ligament, including autografts (patella ligament, fascia), allografts (bone-tendon-bone), and synthetic materials

Modified Extra-Articular Methods

- Fibular head transposition or popliteal tendon transposition
- Realignment and tension on the lateral collateral ligament or popliteal tendon to stabilize the stifle joint

Tibial Plateau Leveling Osteotomy (TPLO)

- Surgical cutting (known as a “rotational osteotomy”) of the tibia
- Held in place with a special plate and screws

Tibial Tuberosity Advancement

- Surgical procedure in which part of the tibia is cut (procedure known as a “tibial crest osteotomy”), crest is held in an advanced position with a cage and plate, bone graft fills the defect
- Active control of cranial tibial displacement is improved which helps stabilize the stifle

Medications

Medications presented in this section are intended to provide general information about possible treatment. The treatment for a particular condition may evolve as medical advances are made; therefore, the medications should not be considered as all inclusive

- Nonsteroidal anti-inflammatory drugs (NSAIDs)—minimize pain; decrease inflammation; examples include meloxicam, carprofen, etodolac, deracoxib
- Medications intended to slow the progression of arthritic changes and protect joint cartilage (known as “chondroprotective drugs”), such as polysulfated glycosaminoglycans, glucosamine, and chondroitin sulfate—may help limit cartilage damage and degeneration; may help alleviate pain and inflammation
- Pain relievers (known as “analgesics”)

Follow-Up Care

PATIENT MONITORING

- Depends on method of treatment
- Most surgical techniques require 2–4 months of rehabilitation

PREVENTIONS AND AVOIDANCE

- Avoid breeding pets with conformational abnormalities

POSSIBLE COMPLICATIONS

- Second surgery may be required in 10% to 15% of cases, because of subsequent damage to the meniscus (a crescent-shaped cartilage located between the femur and tibia in the stifle)
- Approximately 20–40% of dogs with cranial cruciate ligament rupture involving one leg will rupture the ligament in the opposite leg at a later date

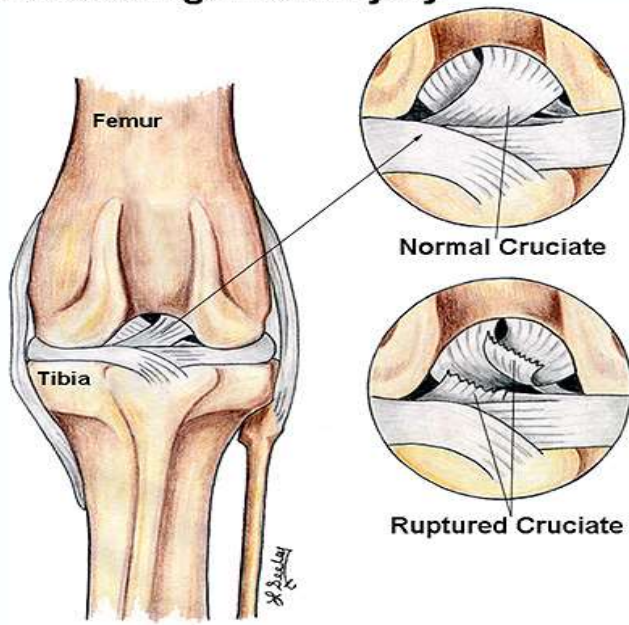
EXPECTED COURSE AND PROGNOSIS

- Regardless of surgical technique, the success rate generally is better than 85%

Key Points

- Regardless of the method of treatment, some degenerative joint disease (progressive and permanent deterioration of joint cartilage) is common
- Approximately 20–40% of dogs with cranial cruciate ligament rupture involving one leg will rupture the ligament in the opposite leg at a later date
- Return to full athletic function is possible but requires considerable rehabilitation

Cruciate Ligament Injury



Normal Cruciate

Ruptured Cruciate